

Ancestry and Pathology in King Tutankhamun's Family

Zahi Hawass, PhD

Yehia Z. Gad, MD

Somaia Ismail, PhD

Rabab Khairat, MSc

Dina Fathalla, MSc

Naglaa Hasan, MSc

Amal Ahmed, BPharm

Hisham Elleithy, MA

Markus Ball, MSc

Fawzi Gaballah, PhD

Sally Wasef, MSc

Mohamed Fateen, MD

Hany Amer, PhD

Paul Gostner, MD

Ashraf Selim, MD

Albert Zink, PhD

Carsten M. Pusch, PhD

THE 18TH DYNASTY (CIRCA 1550-1295 BC) of the New Kingdom (circa 1550-1070 BC) was one of the most powerful royal houses of ancient Egypt. The pharaoh Akhenaten, who ruled from circa 1351 to 1334 BC, is considered one of the most controversial of the Egyptian pharaohs, because his attempt to radically transform traditional religion affected all facets of society and caused great turmoil.

Akhenaten's eventual successor, Tutankhamun, is probably the most famous of all pharaohs, although his tenure was brief. He died in the ninth year of his reign, circa 1324 BC, at age 19 years. Little was known of Tutankhamun and his ancestry prior to Howard Carter's discovery of his intact tomb (KV62) in

For editorial comment see p 667.

Context The New Kingdom in ancient Egypt, comprising the 18th, 19th, and 20th dynasties, spanned the mid-16th to the early 11th centuries BC. The late 18th dynasty, which included the reigns of pharaohs Akhenaten and Tutankhamun, was an extraordinary time. The identification of a number of royal mummies from this era, the exact relationships between some members of the royal family, and possible illnesses and causes of death have been matters of debate.

Objectives To introduce a new approach to molecular and medical Egyptology, to determine familial relationships among 11 royal mummies of the New Kingdom, and to search for pathological features attributable to possible murder, consanguinity, inherited disorders, and infectious diseases.

Design From September 2007 to October 2009, royal mummies underwent detailed anthropological, radiological, and genetic studies as part of the King Tutankhamun Family Project. Mummies distinct from Tutankhamun's immediate lineage served as the genetic and morphological reference. To authenticate DNA results, analytical steps were repeated and independently replicated in a second ancient DNA laboratory staffed by a separate group of personnel. Eleven royal mummies dating from circa 1410-1324 BC and suspected of being kindred of Tutankhamun and 5 royal mummies dating to an earlier period, circa 1550-1479 BC, were examined.

Main Outcome Measures Microsatellite-based haplotypes in the mummies, generational segregation of alleles within possible pedigree variants, and correlation of identified diseases with individual age, archeological evidence, and the written historical record.

Results Genetic fingerprinting allowed the construction of a 5-generation pedigree of Tutankhamun's immediate lineage. The KV55 mummy and KV35YL were identified as the parents of Tutankhamun. No signs of gynecomastia and craniosynostoses (eg, Antley-Bixler syndrome) or Marfan syndrome were found, but an accumulation of malformations in Tutankhamun's family was evident. Several pathologies including Köhler disease II were diagnosed in Tutankhamun; none alone would have caused death. Genetic testing for *STEVOR*, *AMA1*, or *MSP1* genes specific for *Plasmodium falciparum* revealed indications of malaria tropica in 4 mummies, including Tutankhamun's. These results suggest avascular bone necrosis in conjunction with the malarial infection as the most likely cause of death in Tutankhamun. Walking impairment and malarial disease sustained by Tutankhamun is supported by the discovery of canes and an afterlife pharmacy in his tomb.

Conclusion Using a multidisciplinary scientific approach, we showed the feasibility of gathering data on Pharaonic kinship and diseases and speculated about individual causes of death.

JAMA. 2010;303(7):638-647

www.jama.com

Author Affiliations: Supreme Council of Antiquities, Cairo, Egypt (Dr Hawass and Mr Elleithy); National Research Center, Cairo, Egypt (Drs Gad, Ismail, and Amer and Mss Hasan and Ahmed); Ancient DNA Laboratory, Egyptian Museum, Cairo, Egypt (Drs Gad and Ismail and Mss Fathalla, Khairat, Hasan, and Ahmed); Institute of Human Genetics, Division of Molecular Genetics, University of Tübingen, Tübingen, Germany (Ms Khairat, Mr Ball, and Dr Pusch); Learning Resource Center, Kasr Al Ainy Faculty of Medicine, Cairo University, Cairo, Egypt

(Drs Gaballah and Fateen and Ms Wasef); Department of Radiodiagnostics, Central Hospital Bolzano, Bolzano, Italy (Dr Gostner); Department of Radiology, Kasr Al Ainy Faculty of Medicine, Cairo, Egypt (Dr Selim); and Institute for Mummies and the Iceman, EURAC, Bolzano, Italy (Dr Zink).

Corresponding Author: Carsten M. Pusch, PhD, Institute of Human Genetics, Division of Molecular Genetics, University of Tübingen, Wilhelmstraße 27, D-72074, Tübingen, Germany (carsten.pusch@uni-tuebingen.de).

the Valley of the Kings in 1922, but his mummy and the priceless treasures buried with him, along with other important archeological discoveries of the 20th century, have provided significant information about the boy pharaoh's life and family.

Because Tutankhamun died so young and left no heirs, numerous speculations on familial disease have been made. The presence of disease is further supported by numerous reliefs, statuettes, and other sculptures of Akhenaten and his family dating from the Amarna period (circa 1353-1323 BC). These artifacts show the royalty of that era as having a somewhat androgynous appearance or a bizarre form of gynecomastia. Specific diseases that have been suggested to explain this appearance include Marfan syndrome, Wilson-Turner X-linked mental retardation syndrome, Fröhlich syndrome (adiposogenital dystrophy), Klinefelter syndrome, androgen insensitivity syndrome, aromatase excess syndrome in conjunction with sagittal craniosynostosis syndrome, or Antley-Bixler syndrome or a variant form of that syndrome.¹⁻⁴ However, most of the disease diagnoses are hypotheses derived by observing and interpreting artifacts and not by evaluating the mummified remains of royal individuals apart from these artifacts.

To shed light on the putative diseases and causes of death in Tutankhamun's immediate lineage, we first used molecular genetic methods to determine kinship within that lineage. Whereas some individual relationships were known from historical records, the identity of most of the mummies under investigation was still uncertain. We also searched specifically for pathologies, inherited diseases, and causes of death. For example, many scholars have hypothesized that Tutankhamun's death was attributable to an accident, such as a fall from his chariot or a kick by a horse or other animal; septicemia or fat embolism secondary to a femur fracture; murder by a blow to the back of the head; or poisoning.⁵⁻¹⁰ We had access to mummies that had never before been studied with the methods we used.

METHODS

Mummies

In addition to Tutankhamun, 10 mummies possibly or definitely closely related in some way to Tutankhamun were chosen for this 2-year project; of these, the identities were certain for only 3. In addition to these 11 mummies, 5 other royal individuals dating to the early New Kingdom were selected that were distinct from the putative members of the Tutankhamun lineage. These 5 mummies were used as a morphological (excluding Ahmose-Nefertari) and genetic (excluding Thutmose II) control group. All mummies are listed in TABLE 1, and full-body computed tomography reconstructions of the mummies are available in the online feature at <http://www.jama.com>.

Radiology

All of the mummies, except for that of Ahmose-Nefertari, were scanned using a multidetector computed tomography unit (Somatom Emotion 6; Siemens Medical Solutions, Malvern, Pennsylvania) installed on a truck. The tomography unit was used to examine the mummy of Tutankhamun and those of the 2 women from tomb KV35 in Luxor as well as the rest of the mummies at the Egyptian Museum in Cairo (eAppendix, available at <http://www.jama.com>). Cephalic indices of mummy heads were determined according to the method of Weber et al.¹¹

Molecular Genetics

We adopted the previously published criteria for ancient DNA authentication, which form a consensus outline for executing research studies using ancient DNA (eAppendix).^{12,13} Sampling of bone tissue and DNA extraction and purification were performed according to protocols previously published.^{14,15} Negative and blank extraction controls were processed along with each sample. In addition, water and other aqueous polymerase chain reaction (PCR) components were monitored using the sensitive internal-Alu-PCR protocol¹⁶ to assess contamination with modern human DNA.

Sixteen Y-chromosomal short tandem repeats (DYS456, DYS389I, DYS390, DYS389II, DYS458, DYS19, DYS385, DYS393, DYS391, DYS439, DYS635, DYS392, Y-GATA-H4, DYS437, DYS438, DYS448) were amplified according to the manufacturer's protocol using the AmpFSTR Yfiler PCR amplification kit (Applied Biosystems, Foster City, California). The Identifier kit and the AmpFSTR Minifiler kit (Applied Biosystems) were used for amplification of 8 polymorphic microsatellites of the nuclear genome (D13S317, D7S820, D2S1338, D21S11, D16S539, D18S51, CSF1PO, FGA).

To test for *Plasmodium falciparum* DNA, PCR primers were designed that specifically amplify small subtelomeric variable open reading frame (STEVOR), apical membrane antigen 1 (AMA1), and merozoite surface protein 1 (MSP1) gene fragments with sizes of 100 to 250 base pairs (bp). PCR products and cloned DNA fragments were sequenced by the Sanger method (eAppendix). Purified amplicons were run on a genetic analyzer (ABI Prism 3130, Applied Biosystems). Microsatellites were interpreted with Data Collection Software version 3.0 and GeneMapper ID version 3.2 (Applied Biosystems). Lasergene version 8.0 (DNASTAR, Madison, Wisconsin) and BioEdit version 7.0.9 (Ibis Biosciences, Carlsbad, California) were used to establish multisequence alignments (eAppendix).

RESULTS

Kinship Analyses

To elucidate the genealogy in Tutankhamun's family, microsatellite markers were used to achieve genetic fingerprints of all mummies. All 8 females tested were negative for the examined polymorphic Y-chromosomal loci, underlining the specificity of the approach. The repeated search for hemizygous Y alleles in the males yielded few results, with differing success in the various markers contained in the multiplex PCR kit used. Markers DYS393 and Y-GATA-H4 showed identical allele constellations (repeat motif located in the mi-

cross-satellite allele reiterated 13 and 11 times, respectively) in Amenhotep III, KV55, and Tutankhamun but different allelotypes in the nonrelated CCG61065 sample from TT320 (9 and 9, respectively). Syngeneic Y-chromosomal DNA in the 3 former mummies indicates that they share the same paternal lineage.

These results were repeatedly obtained with DNA extracted from 2 to 4 different biopsies per mummy; moreover, they differed from the Y profiles of the male laboratory staff and were independently reproduced twice in a second laboratory physically isolated from the first, data-generating laboratory.

An up to 30-fold testing of polymorphic autosomal microsatellite loci via the combined use of the Identifiler and AmpFSTR Minifiler kits (Applied Biosystems) yielded complete data sets for all 8 markers in 7 mummies (Thuya, Yuya, Amenhotep III, Tutankhamun, KV55, and both female mummies from KV35) but

Table 1. Characteristics of the Royal 18th-Dynasty Mummies Under Investigation (N = 16)

Tomb	Excavator, Discovery Date	Mummy	Sex	Age, y	Previously Supposed Identity	Status, Reign	Storage
KV62	H. Carter, 1922	Tutankhamun	M	19	Identified, likely son of Akhenaten, Amenhotep III, or Smenkhkare	Pharaoh, circa 1333-1324 BC	KV62, Luxor
Putative Members of the Tutankhamun Lineage							
KV46	J. Quibell and T. M. Davis, 1905	Thuya	F	50-60	Identified, grandmother or great grandmother of Tutankhamun, mother of Tiye	Noblewoman, ^a circa 1410-1360 BC	Egyptian Museum, Cairo
		Yuya	M	50-60	Identified, grandfather or great grandfather of Tutankhamun, father of Tiye	Nobleman, ^a circa 1410-1360 BC	Egyptian Museum, Cairo
KV55	E. Ayrton, 1907	KV55	M	35-45 ^b	Smenkhkare, Akhenaten	Pharaoh, circa 1351-1334 BC	Egyptian Museum, Cairo
KV35	V. Loret, 1898	Amenhotep III	M	≥50	Identified, father of Akhenaten	Pharaoh, circa 1388-1351 BC	Egyptian Museum, Cairo
		KV35YL	F	25-35	Nefertiti, 18th-dynasty queen or princess	Queen, ^a circa 1370-1330 BC; noblewoman ^a	KV35, Luxor
		KV35EL	F	50	Nefertiti, Tiye, 18th-dynasty queen	Queen, ^a circa 1388-1351 BC; Queen, circa 1370-1330 BC	KV35, Luxor
KV62	H. Carter, 1922	Fetus 1	F	5 mo	Tutankhamun's daughter	Princess	Kasr El Ainy, Faculty of Medicine, Cairo University
		Fetus 2	F	7 mo	Tutankhamun's daughter	Princess	Kasr El Ainy, Faculty of Medicine, Cairo University
KV21	G. B. Belzoni, 1817 (reinvestigated by D. Ryan, 1989)	KV21A	F	25-40	18th-dynasty queen or princess	Royal female, noblewoman	Egyptian Museum, Cairo
		KV21B	F	25-40	18th-dynasty queen or princess	Royal female, noblewoman	Egyptian Museum, Cairo
Morphological and Genetic Control Group of 18th-Dynasty Mummies							
TT320	Initially discovered by the Abd er Rassul family, official discovery 1881; tomb cleared by É. Brugsch, 1881	CCG61065	M	≈30	Originally thought to be Thutmose I, the father of Hatshepsut; long considered an unidentified royal of the 18th dynasty	Royal male	Egyptian Museum, Cairo
		Thutmose II (CCG61066)	M	≈30	Identified, son of Thutmose I, half-brother and husband of Hatshepsut	Pharaoh, circa 1492-1479 BC	Egyptian Museum, Cairo
		Ah-mose-Nefertari (CCG61055)	F	70	Identified, queen and sister of Ah-mose I, possibly grandmother of Hatshepsut	Queen, circa 1550-1525 BC	Egyptian Museum, Cairo
KV60 Original tomb KV20	G. B. Belzoni, 1817 (excavated by H. Carter, 1903-1904)	Hatshepsut (KV60A)	F	≈50	Identified, Hatshepsut, daughter of Thutmose I	Queen, Pharaoh, circa 1503-1482 BC	Egyptian Museum, Cairo
		Sitra-In (KV60B)	F	≈50	Identified, Sitra-In, royal wet nurse of Hatshepsut	Noblewoman, circa 1540-1490 BC ^a	Egyptian Museum, Cairo

Abbreviations: EL, elder lady; KV, Valley of the Kings Thebes; TT, Theban Tomb at Deir el-Bahari; YL, younger lady.

^aEstimated lifetime.

^bThe mummy in KV55 was previously thought to be in his 20s when he died. However, our new computed tomography investigation revealed that he lived to be much older.

Figure 1. Microsatellite Data of Mummies Thought to Belong to the Tutankhamun Kindred

	Microsatellite markers							
	D13S317	D7S820	D2S1338	D21S11	D16S539	D18S51	CSF1PO	FGA
Thuya (KV46)	9 12	10 13	19 26	26 35	11 13	8 19	7 12	24 26
Yuya (KV46)	11 13	6 15	22 27	29 34	6 10	12 22	9 12	20 25
KV35EL ^{a,c}	11 12	10 15	22 26	26 29	6 11	19 22	9 12	20 26
Amenhotep III (KV35)	10 16	6 15	16 27	25 34	8 13	16 22	6 9	23 31
KV55 ^{b,c}	10 12	15 15	16 26	29 34	11 13	16 19	9 12	20 23
KV35YL ^c	10 12	6 10	16 26	25 29	8 11	16 19	6 12	20 23
Tutankhamun (KV62) ^c	10 12	10 15	16 26	29 34	8 13	19 19	6 12	23 23
KV21A	10 16		26	35	8	10	12	23
KV21B	10		17 26		11 13		12	
Fetus 1 (KV62)	12 16	10 13	16	29	8	19	12	23
Fetus 2 (KV62)	10	6 15	26	29 35	8 13	10 19	12	23

Origin of transmitted alleles based on kinship analysis

- n Thuya
- n Yuya
- n Amenhotep III
- n Nontransmitted alleles
- n = number of repeat motif reiterations at locus
- No data obtained

The length of each microsatellite allele was determined in base pairs and converted by software into the number of actual reiterations of repeat motifs at the corresponding locus. All established genotypes differ from those of the laboratory staff and the ancient control group. Note that allele origins in KV21A and KV21B are suggestive and do not serve as proof of relationship with the Amenhotep III and Thuya lineages. See online interactive kinship analysis and pedigree.

^aIdentified as Tiye. See eAppendix for additional commentary.

^bIdentified as Akhenaten. See eAppendix for additional commentary.

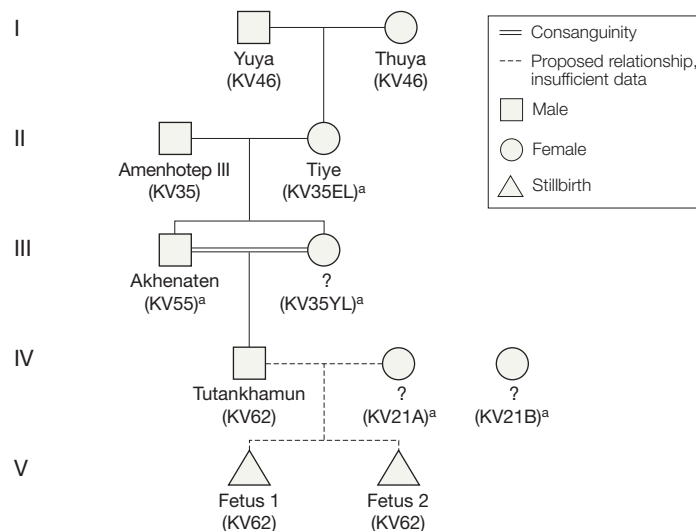
^cData replication was successfully performed in the second Cairo laboratory.

only partial data for both KV62 fetuses and the KV21A and KV21B mummies (FIGURE 1). Repeated attempts to complete the profiles in the 4 latter mummies were not successful; however, we were able to replicate some of the results for the previous mummies more than 4 times in the second, independent laboratory (Figure 1). Moreover, because these profiles differed from those of the laboratory staff and were not identical to the ones established for the control group, the data were considered authentic.

Based on the partial Y-chromosomal information on the amount of autosomal half-allele sharing and family trio likelihood calculation, the most plausible 5-generation pedigree was constructed. We identified Yuya and Thuya as great-grandparents of Tutankhamun, Amenhotep III and KV35EL as his grandparents, and the KV55 male and KV35YL as his sibling parents (Figure 1, FIGURE 2, and online interactive kinship analysis and pedigree; for details on kinship statistics, see eAppendix).

Gynecomastia, Feminity, and Syndromes

The most prominent feature exhibited by the art of the pharaoh Akhenaten, seen also to a lesser degree in the statues and

Figure 2. Pedigree Showing the Genetic Relationships of the Tested 18th-Dynasty Mummies

Double line, indicating consanguinity, here represents a first-degree brother-sister relationship. Fetus 1 and fetus 2 can be daughters of Tutankhamun; however, the mother is not yet genetically identified. The data obtained from KV21A suggest her as the mother of the fetuses. However, the few data are not statistically significant to define her as Ankhensnamun. See online interactive kinship analysis and pedigree.

^aSee eAppendix for additional commentary on identity.

reliefs of Tutankhamun, is a markedly feminized appearance (eFigure 1A-C), reasonably suggesting some form of gynecomastia or Marfan syndrome as an underlying disease.¹⁻⁴ However, putative breasts in Tutankhamun and his father Akhenaten (KV55) cannot be de-

termined, because KV55 is a mummified skeleton and Tutankhamun lacks the frontal part of the chest wall. The penis of Tutankhamun, which is no longer attached to the body, is well developed. Furthermore, the pelvic bones of Tutankhamun are almost entirely missing,

and the pelvis of KV55, which is present but fragmented, does not show feminine traits after reconstruction using computed tomography (eAppendix, eFigure 1D-G, and online interactive feature).

One of the obvious features of Marfan syndrome is dolichocephaly.¹⁷⁻¹⁹ With the exception of Yuya (cephalic index, 70.3), none of the mummies of the Tutankhamun lineage has a cephalic index of 75 or less (ie, indicating dolichocephaly). Instead, Akhenaten has an index of 81.0 and Tutankhamun an index of 83.9, indicating brachycephaly. From the control group, Thutmose II and the TT320-CCG61065 mummy show dolichocephaly, with cephalic indices of 73.4 and 74.3, respectively. Because there is no sign of premature closure of sutures, none

of the skull shapes can be considered pathological. The complex diagnosis of Marfan syndrome is based on certain combinations of major and minor clinical features.¹⁸ Following this classification, a Marfan diagnosis cannot be supported in these mummies. (TABLE 2). Antley-Bixler syndrome is also excluded in Tutankhamun and Akhenaten because their brachycephaly is not attributable to craniosynostoses, and further signs of Antley-Bixler or other syndromes are missing or unspecific.

Pathology in the Royal Mummies

Tutankhamun's mummy was examined several times radiologically.²⁰⁻²³ Our inspection of the skull and trunk did not reveal novel information, but detailed examination of the king's feet

yielded new data. Compared with the normal anatomy of the foot (FIGURE 3), the right foot had a low arch (Rocher angle, 132°; normal value, 126°). The medial longitudinal arch of the left foot was slightly higher than normal (Rocher angle, 120°) (FIGURE 4A), with the forefoot in supine and inwardly rotated position akin to an equinovarus foot deformity (Figure 4B). There were no pathological findings on the bone structure of the right metatarsal heads (FIGURE 5A). In contrast, the left second metatarsal head was strongly deformed and displayed a distinctly altered structure, with areas of increased and decreased bone density indicating bone necrosis (Figure 5B). The study further showed a widening of the second metatarsophalangeal joint space,

Table 2. Evaluation of Marfanoid Features in the Collection of Royal 18th-Dynasty Mummies Under Investigation^a

Marfanoid Features	Tutankhamun Lineage										Control Group				
	Tutankhamun (KV62)	Thuya (KV46)	Yuya (KV46)	Akhenaten (KV55)	Amenhotep III (KV35)	KV35YL	Tiye (KV35EL)	Fetus 1 (KV62) ^b	Fetus 2 (KV62) ^b	KV21A	KV21B	TT320-CCG61065	Thutmose II (TT320-CCG61066)	Hatshepsut (KV60A)	Sitra-In (KV60B)
Major criteria															
Dolichostenomelia	-	-	-	-	-	-	-	-	-	-	-	-	-	-	-
Body height, cm	167	150	166	160	160	158	145	27.5	38	<150	<150	157	173	153	151
Scoliosis, kyphoscoliosis	+ ^c	+ ^d	-	+ ^c	-	+ ^c	+ ^c	-	+ ^c	+ ^c	+ ^c	+ ^c	+ ^c	-	+ ^c
Pectus carinatum	NA	-	-	NA	NA	-	-	NA	NA	NA	NA	-	NA	-	-
Pectus excavatum	NA	-	-	NA	NA	-	-	NA	NA	NA	NA	-	NA	-	-
Acetabular protrusion	NA	-	-	-	-	-	-	NA	NA	-	-	-	-	-	-
Pes planus	+ ^{c,e}	-	-	NA	-	NA	-	NA	NA	-	-	-	-	-	-
Minor criteria															
Dolichocephaly	-	-	+ ^{c,f}	-	-	-	-	NA	NA	NA	NA	+ ^{c,f}	+ ^{c,f}	-	-
Arachnodactyly	-	- ^g	- ^g	NA	NA	-	- ^g	-	-	-	-	NA	-	-	-
Mandibular retrognathism	+	+	-	+	+	+	-	NA	NA	NA	NA	-	+	+	-
Hypoplasia of cheek bones	-	-	-	+	-	+	-	NA	NA	NA	NA	-	-	-	-
Highly arched palate	+	-	-	+	+	-	-	NA	NA	NA	NA	-	-	-	-
Crowding of teeth	+	-	-	+	-	+	-	NA	NA	NA	NA	-	+	-	-
Striae atrophicae	-	-	-	NA	NA	-	-	NA	NA	NA	NA	-	-	-	-
Mitral annular calcification	NA	-	-	NA	NA	NA	NA	NA	NA	NA	NA	-	+	-	NA
CCA feature (rumpled helix of the ear)	-	-	-	NA	NA	-	+	NA	NA	NA	NA	-	+	-	+

Abbreviations: CCA, congenital contractural arachnodactyly; EL, elder lady; minus symbol, feature absent; NA, not available (certain parts of the mummies are missing or fragmented, ie, feature cannot be observed); plus symbol, feature present; YL, younger lady.

^aNo computed tomography scan was performed on the mummy of Ahmose-Nefertari (TT320-CCG61055).

^bMany of the features cannot be evaluated in fetuses.

^cMild form.

^dCobb angle in Thuya, >20° (severe form of scoliosis or kyphoscoliosis); in all other individuals, <20° (mild form).

^ePes planus in Tutankhamun is not caused by a medial displacement of the inner malleolus (ie, no marfanoid flatfoot).

^fShape of the head is of natural occurrence, ie, not caused by craniosynostosis syndromes.

^gMadonna fingers.

with a normal articulating surface of the proximal phalanx. The third metatarsal head was only slightly deformed; the bony structure, however, showed signs of bone necrosis. The remaining left metatarsal heads appeared to be of normal structure (Figure 5B). The plantar surface of the left second metatarsal head shows a crater-shaped bone and a soft tissue defect in the area of bone necrosis (Figure 5C). The second and third toes on the left foot are in abduction. The second toe is shortened because it lacks the middle phalanx (oligodactyly [hypophalangism]). The proximal phalanx directly articulates with the distal phalanx (Figure 5D).

Except for Ahmose-Nefertari, all remaining mummies were subjected to radiological analyses. Along with various bony malformations (eg, cleft palate, kyphoscoliosis, clubfeet, flat feet) in the remaining mummies, indications of bone degeneration, neoplastic changes, and trauma were also found. These various findings are listed in TABLE 3 and are described in the eAppendix.

Infectious Diseases

Various infectious diseases are suspected or known to have been prevalent in antiquity,²⁴⁻²⁷ and some are described in remarkable detail in Egyptian papyri (eg, Papyrus Ebers, circa 1520 BC). Positive results were not found for pandemic plague (Black Death, bubonic plague), tuberculosis, leprosy, or leishmaniasis, but we identified DNA of *P falciparum* (the malaria parasite) in several of the royal mummies. Amplification of the *P falciparum* STEVOR gene family²⁸ repeatedly yielded 149-bp and 189-bp amplicons for Tutankhamun and the TT320-CCG61065 mummy and also yielded a faint PCR band using DNA of the Yuya mummy. This result was replicated in further PCRs using DNA from other biopsies (for details on STEVOR data see eAppendix and eFigure 2).

To consolidate or disprove this result, we targeted a further *Plasmodium* gene using new DNA extracts from the

royal mummies in our study. We identified 4 mummies as positive for AMA1, a merozoite protein responsible for the successful binding of the parasite to the erythrocyte membrane, by amplifying DNA fragments locating to the conserved region of the AMA1 gene (FIGURE 6). The AMA1 PCR fragments were obtained for all mummies testing positive in the earlier STEVOR assays (ie, Tutankhamun, Yuya, TT320-CCG61065). In addition, we also obtained a positive typing for Thuya. Repetition of these experiments in the second laboratory using DNA extrac-

tions from new biopsies confirmed the previous data (Figure 6; for details on AMA1 data, see eAppendix).

In addition to the STEVOR and AMA1 genes, we attempted amplification of alleles of the MSP1 and MSP2 genes specific to *P falciparum*. Because of the fragmented nature of the ancient DNA, we did not obtain positive amplifications when targeting the larger (>400 bp) PCR alleles of the MSP2 gene but were successful in amplifying different alleles of the MSP1 gene (for details on MSP1 data, see eAppendix).^{29,30} Using extracts from Tutankhamun and Yuya, we

Figure 3. Normal Foot Anatomy

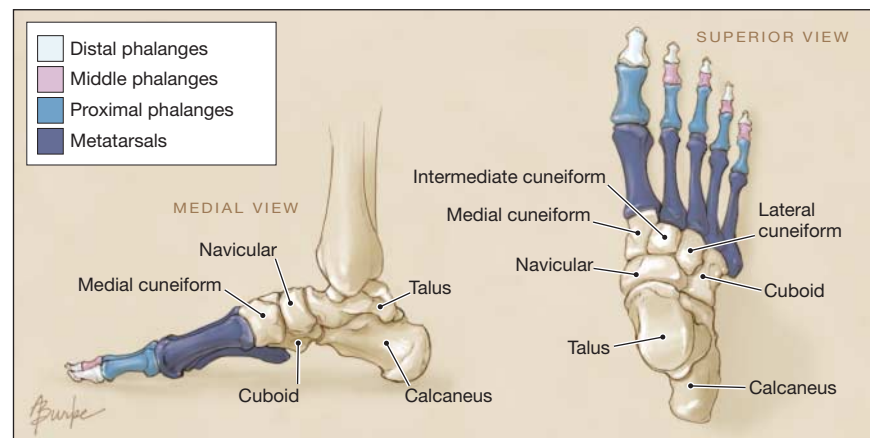
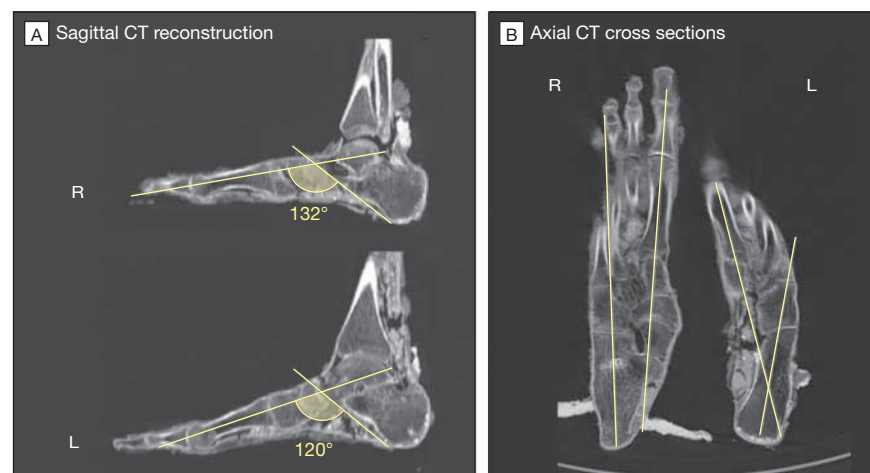


Figure 4. Analysis of Malformations in the Feet of Tutankhamun



A, As indicated by the angle between the axis of the first metatarsal and the line between the lowest point of the calcaneal tuberosity to the lowest point of the calcaneocuboid articulation (Rocher angle), the arch of the right foot is flat (132°) compared with that of the left (120°). The Rocher angle of a normal foot is 126° . B, The supine and inwardly rotated position of the left foot are further features of clubfoot.

repeatedly amplified the RO33 and MAD20 alleles, which is indicative of at least a double infection with the *P falciparum* parasite. The DNA of Thuya yielded amplicons for the RO33 allele. The DNA of TT320-CCG61065 was refractory to *MSP1* amplifications. Cloning the obtained allelic fragments into TA plasmid vectors and subsequent Sanger sequencing of 21 clones designated the sequences as specific for *MSP1* (eAppendix).

COMMENT

Kinship Determination

More than 55 bone biopsies were used to elucidate the individual relationships of 18th-dynasty individuals, with the result that several of the anonymous mummies or those with suspected identities are now able to be addressed by name. These include KV35EL, who is Tiye, mother of Akhenaten and grandmother of Tutankhamun, and the KV55 mummy, who

is most probably Akhenaten, father of Tutankhamun (Figure 2, eAppendix, and online interactive kinship analysis and pedigree). The latter kinship is supported in that several unique anthropological features are shared by the 2 mummies and that the blood group of both individuals is identical.^{31,32}

Disease or Amarna Artistic Style?

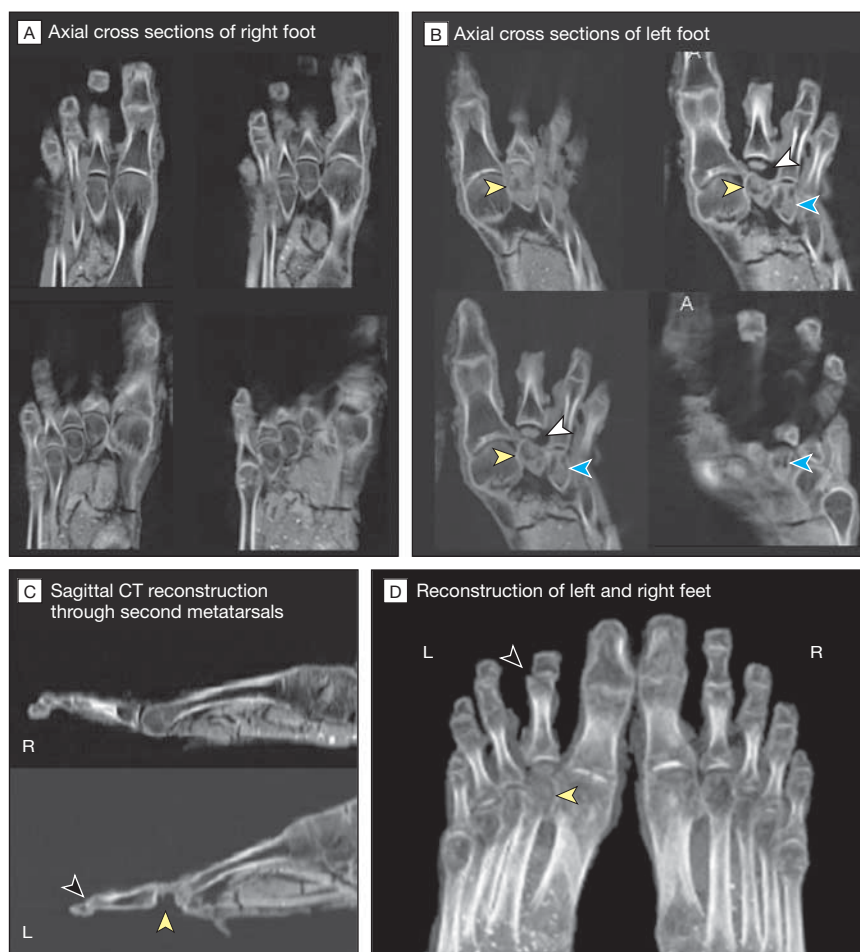Macroscopic and radiological inspection of the mummies did not show specific signs of gynecomastia, craniosynostoses, Antley-Bixler syndrome or deficiency in cytochrome P450 oxidoreductase, Marfan syndrome, or related disorders (eAppendix, Table 2). Therefore, the particular artistic presentation of persons in the Amarna period is confirmed as a royally decreed style most probably related to the religious reforms of Akhenaten. It is unlikely that either Tutankhamun or Akhenaten actually displayed a significantly bizarre or feminine physique.

It is important to note that ancient Egyptian kings typically had themselves and their families represented in an idealized fashion. A recent radiographic examination of the Nefertiti bust in the Berlin Museum illustrates this clearly by showing that the original face of Nefertiti, present as a thin layer beneath the outer surface, is less beautiful than that represented by the artifact.³³ Differences include the angles of the eyelids, creases around the corners of the mouth on the limestone surface, and a slight bump on the ridge of the nose.³⁴ Thus, especially in the absence of morphological justification, Akhenaten's choice of a "grotesque" style becomes even more significant.

Walking Impairment and Canes

Tutankhamun had a juvenile aseptic bone necrosis of the left second and third metatarsals (Köhler disease II, Freiberg-Köhler syndrome). The widening of the metatarsal-phalangeal joint space, as well as secondary changes of the second and third metatarsal heads, indicate that the disease was still flourishing at the time of death.³⁵ Bone and soft tissue loss at

Figure 5. Analysis of Pathology in the Feet of Tutankhamun



A, The heads of all metatarsal bones as well as metatarsal phalangeal articulations of the right foot are clearly discernable and completely preserved. B, In the left foot, the second metatarsal bone head (yellow arrowheads) shows signs of bone necrosis accompanied by anterior displacement of the second toe and widening of the second metatarsophalangeal joint space (white arrowheads). The third metatarsal bone head is similarly deformed (blue arrowheads), displaying features of bone necrosis as well. Metatarsal bone heads 1, 4, and 5 are normal in size and structure. C, The right foot shows no pathological findings. The second metatarsal bone head shows evidence of necrosis with loss of bone substance and soft tissue (yellow arrowhead). The second toe of the left foot lacks the middle phalanx (oligodactyly [hypophalangism], black arrowhead). D, The right foot shows no pathological findings. In the left foot, the second metatarsal head is necrotic (yellow arrowhead) and the second toe is missing the middle phalanx (oligodactyly [hypophalangism], black arrowhead), is anteriorly displaced, and the distal phalanx is subluxated.

Table 3. Anomalies and Diseases in This Collection of 18th-Dynasty Mummies

Mummy	Malformations	Other Pathologies and Diseases
Tutankhamun (KV62)	Cleft palate, mild clubfoot left, pes planus right, oligodactyly (hypophalangism) right, mild kyphoscoliosis	Leg fracture of type 33C3, ^a Köhler disease II, malaria tropica ^b
Tutankhamun kindred Thuya (KV46)	Severe kyphoscoliosis	Dental granuloma, arteriosclerosis, incisional hernia, malaria tropica
Yuya (KV46)	None	Dental granuloma, incisional hernia, malaria tropica
Akhenaten (KV55)	Cleft palate, scoliosis	Osteoma in the maxillary sinus, femoral osseous collapse, or bone fibroma
Amenhotep III (KV35)	Clubfoot	Caries, dental granuloma, bony erosions 2-3 cm at the inner table and diploe of the right parietal bone, spondylarthrosis
KV35YL	Scoliosis	Traumatic events (face, calvarium) ^b
Tiye (KV35EL)	Mild scoliosis	Struma, incisional hernia
Fetus 1 (KV62)	None	Stillbirth
Fetus 2 (KV62)	Mild scoliosis	Stillbirth
KV21A	Scoliosis, clubfeet	None
KV21B	Scoliosis, clubfoot	None
Control Group TT320-CCG61065	Kyphoscoliosis, pelvic obliquity	Incisional hernia, malaria tropica, arrow wound to chest ^b
Thutmose II (TT320-CCG61066)	Kyphoscoliosis, hollow feet (pes cavus)	Calcified heart valves, incisional hernia
Hatshepsut (KV60A)	None	Dental abscess, ^b incisional hernia, slipped disk (L5-S1), putative metastatic cancer left iliac bone ^b
Sitra-In (KV60B)	Kyphoscoliosis	Incisional hernia

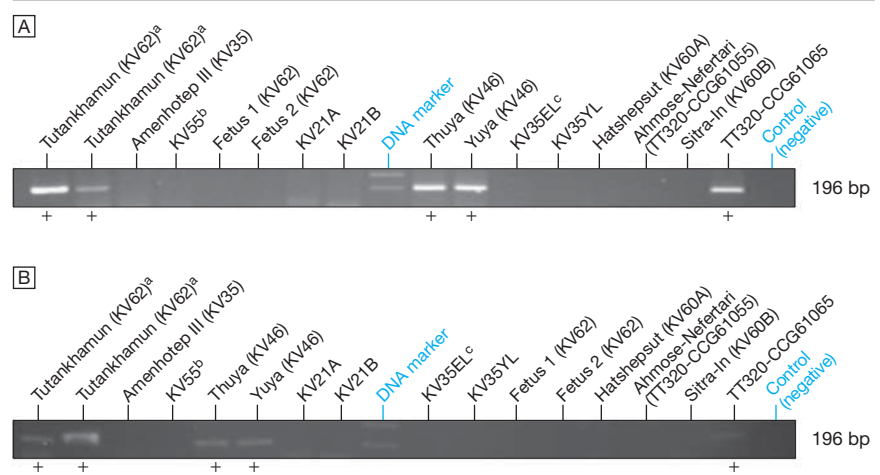
Abbreviations: CCG, Cairo Catalogue Général; KV, Valley of the Kings Thebes; TT, Theban Tomb at Deir el-Bahari.

^aAO classification.

^bAssumed cause of death.

the second metatarsal phalangeal articulation could further indicate that an acute inflammatory condition was present on the basis of an ulcerative osteoarthritis and osteomyelitis. The congenital equinovarus deformity (pes equinovarus) together with the malformed second toe of the left foot (oligodactyly [hypophalangism]) transferred additional joint load to the right foot, causing flattening of the foot arch (pes planus).

There is evidence that Tutankhamun may have had this impairment for quite some time. The walking disability can be substantially aided by the use of a cane. Howard Carter discovered 130 whole and partial examples of sticks and staves (eFigure 3A) in the king's tomb, supporting the hypothesis of a walking impairment.³⁶ Traces of wear can be seen on a number of the sticks, demonstrating that they were used in the king's lifetime (eFigure 3B). Additional evidence for some sort of physical disability is found in a number of 2-dimensional images from Tutankhamun's reign that show him seated while engaged in activities for which he

Figure 6. Identification of Plasmodial DNA in 18th-Dynasty Mummies

A, Polymerase chain reaction amplification of a 196–base pair (bp) apical membrane antigen 1 (AMA1) fragment of *Plasmodium falciparum* in Egyptian mummies. DNA marker indicates molecular size marker phiX/174 *Hae*III. Successful amplification is indicated by “+.” B, Independent replication of the AMA1 data shown in panel A.

^aDifferent DNA extractions.

^bIdentified as Akhenaten. See eAppendix for additional commentary.

^cIdentified as Tiye. See eAppendix for additional commentary.

normally should have been standing, such as hunting (eAppendix and eFigure 3C).^{37,38}

Malaria Tropica

Macroscopic studies revealed areas of patchy skin changes on the pharaoh's

left cheek and neck of uncertain anamnesis, possibly indicating an Aleppo boil, a plague spot, an inflamed mosquito bite, or a mummification artifact.³⁹ However, the genetic identification and typing of plasmodial DNA in Tutankhamun, Thuya, Yuya, and TT320-CCG61065 showed that they must have had malaria tropica, the most severe form of malaria (eAppendix).

Literary evidence for malaria infection dates back to the early Greek period, when Hippocrates described the periodic fever typical of this disease.⁴⁰ Although it is believed that malaria widely affected early populations before Hippocrates,^{27,41} until now only 1 report using immunological tools⁴² and few molecular genetic studies have clearly identified *P falciparum* in ancient specimens.⁴³⁻⁴⁶ We not only identified this parasite in our sample but also observed individual differences in some of the gene sequences as well as different *MSP1* allele constellations in the 4 positive mummies. The diversity of plasmodial DNA (ie, variability in the genes' base order, length polymorphisms, or both) is a well-known phenomenon; however, some of the base deviations were not found in current DNA databases. Further research is required to typify these alterations in more detail and to assign these potentially unknown patterns to ancient Egyptian *Plasmodium* strains that date back to 3300 to 3400 years before present.

To our knowledge, this is the oldest genetic proof for malaria in precisely dated mummies. When the infection occurred, its severity, and whether it could have caused the death in the 4 mummies testing positive is not known. Preliminary data show that Tutankhamun and Yuya had multiple infections, as could be seen by the presence of the 2 *P falciparum* alleles MAD20 and RO33 of the *MSP1* in the extracts. In contrast, and taking only the *MSP1* test system into account, Thuya was infected by only 1 strain, which displayed the RO33 allele.

To date, no association has been found between *P falciparum* *MSP1*

genotypes and the clinical status of persons affected.⁴⁷ We note that mixed *P falciparum* infections were detected in up to 78% of a contemporary sampling, and even isolates from symptomatic children contained more than 1 *Plasmodium* clone.^{47,48} Thus, multiple infections appear to be the norm rather than the exception. Moreover, the *MSP1* allele frequencies tend to vary largely in different, sometimes even neighboring, areas but also over time.²⁹ Thus, the prevalence rate of infection is not known—nor is it known if malaria was an epidemic or an endemic disease and how widely it was distributed in ancient Egypt.

Unfortunately, there is also no distinct evidence in ancient Egyptian texts of treatments for malaria, and there are no references to the fevers and chills associated with the disease.⁴⁹ However, the Nile Delta and the fringes of the Nile Valley were marshy areas and thus excellent breeding grounds for the mosquito genus *Anopheles*. Interestingly, mosquitoes are mentioned in at least 1 ancient text,⁵⁰ and it has also been suggested that the wooden frame of Queen Hetepheres (fourth dynasty) served as the support for a mosquito net.⁵⁰ Herodotus also mentions that Lower Egypt was infested with mosquitoes or other insects and that people slept under nets to avoid them.⁵¹ Since there is nothing in the historical or archeological record that speaks against the widespread presence of this carrier in Pharaonic times, there is no evidence that can be used to argue against the diagnosis of malaria.

Cause of Death

Caution must be taken when interpreting cause of death in these mummies. It can be speculated that Yuya and Thuya had malaria, but it is not known if this was lethal (Table 3). Surprisingly, both individuals had reached an advanced (for the time) age of approximately 50 years or older (Table 1). This means either that the infection took place quite late in their lifetime, that they enjoyed strong genetic fitness, or that they acquired a partial immunity

against the pathogen during their lives. Not every person infected with *P falciparum* becomes gravely ill, and this is especially true in populations that have been exposed to malaria pathogens over long periods.⁵² If Yuya and Thuya spent much of their time living in malaria-endemic areas close to the marshes of the Nile River, partial immunization may have contributed to their survival.

On the other hand, Tutankhamun had multiple disorders, and some of them might have reached the cumulative character of an inflammatory, immune-suppressive—and thus weakening—syndrome (Table 3). He might be envisioned as a young but frail king who needed canes to walk because of the bone-necrotic and sometimes painful Köhler disease II, plus oligodactyly (hypophalangism) in the right foot and clubfoot on the left. A sudden leg fracture²³ possibly introduced by a fall might have resulted in a life-threatening condition when a malaria infection occurred. Seeds, fruits, and leaves found in the tomb, and possibly used as medical treatment, support this diagnosis (eAppendix, eFigures 3D and 3E).^{24,25,53-57}

In conclusion, this study suggests a new approach to research into the molecular genealogy and pathogen paleogenomics of the Pharaonic era. With additional data, a scientific discipline called molecular Egyptology might be established and consolidated, thereby merging natural sciences, life sciences, cultural sciences, humanities, medicine, and other fields.

Author Contributions: Drs Hawass, Gad, Zink, and Pusch had full access to all of the data in the study and take responsibility for the integrity of the data and the accuracy of the data analysis.

Study concept and design: Hawass, Gad, Zink, Pusch.
Acquisition of data: Hawass, Gad, Ismail, Khairat, Fathalla, Hasan, Ahmed, Elleithy, Gaballah, Wasef, Fateen, Amer, Gostner, Selim, Zink.

Analysis and interpretation of data: Hawass, Gad, Ismail, Khairat, Fathalla, Hasan, Ahmed, Elleithy, Wasef, Fateen, Amer, Gostner, Selim, Zink, Pusch.

Drafting of the manuscript: Hawass, Gad, Zink, Pusch.
Critical revision of the manuscript for important intellectual content: Hawass, Gad, Ismail, Khairat, Fathalla, Hasan, Ahmed, Elleithy, Ball, Gaballah, Wasef, Fateen, Amer, Gostner, Selim, Zink, Pusch.

Statistical analysis: Ball, Gostner, Zink, Pusch.
Administrative, technical, or material support: Hawass, Gad, Ismail, Hasan, Ahmed, Elleithy, Ball, Gaballah, Fateen, Amer, Selim, Zink, Pusch.

Study supervision: Gad, Ismail, Zink, Pusch.

Financial Disclosures: None reported.

Funding/Support: This study was supported by the Discovery Channel and the Brando Quilici production group. Funding was also obtained from the Mini-Graduierkolleg Tübingen and the DAAD (GERLS exchange program). Siemens Medical donated material and installed the multislice computed tomography scanner used in the study.

Role of the Sponsor: The funding organizations had no role in the design and conduct of the study; the collection, analysis, and interpretation of the data; or the preparation, review, or approval of the manuscript.

Online-Only Material: The eAppendix, eFigures 1 through 3, and the online feature showing full-body computed tomography reconstructions of the mummies and interactive kinship analysis and pedigree are available at <http://www.jama.com>.

Additional Contributions: Jessica Sherry, BS (manager, first laboratory), and Milena Gozzo, BDM (manager, second laboratory), contributed expert management of the ancient DNA laboratories in Cairo, Egypt. Neither of these individuals received compensation for their contributions beyond their salaries.

REFERENCES

- Paulshock BZ. Tutankhamun and his brothers: familial gynecostasia in the Eighteenth Dynasty. *JAMA*. 1980;244(2):160-164.
- Braverman IM, Redford DB, Mackowiak PA. Akhenaten and the strange physiques of Egypt's 18th dynasty. *Ann Intern Med*. 2009;150(8):556-560.
- Farag TI, Iskandar A. Tutankhamun's paternity. *J R Soc Med*. 1998;91(5):291-292.
- Walshe JM. Tutankhamun: Klinefelter's or Wilson's? *Lancet*. 1973;1(7794):109-110.
- Boyer RS, Rodin EA, Grey TC, Connolly RC. The skull and cervical spine radiographs of Tutankhamen: a critical appraisal. *AJNR Am J Neuroradiol*. 2003;24(6):1142-1147.
- Brier B. *The Murder of Tutankhamen: A True Story*. New York, NY: GP Putnam's Sons; 1998.
- Harrison RG. Post mortem on two pharaohs: was Tutankhamen's skull fractured? *Buried Hist*. 1971;4:114-129.
- King MR. *Who Killed King Tut?* Amherst, NY: Prometheus Press; 2004.
- Counsell DJ. Tutankhamun's murder: case re-opened. *Ancient Egypt*. 2008;10(11):34-40.
- Harer WB. *Chariots, Horses or Hippos: What Killed Tutankhamun?* London, UK: Minerva; 2007.
- Weber J, Collmann H, Czarnetzki A, Spring A, Pusch CM. Morphometric analysis of untreated adult skulls in syndromic and nonsyndromic craniosynostosis. *Neurosurg Rev*. 2008;31(2):179-188.
- Roberts C, Ingham S. Using ancient DNA analysis in paleopathology: a critical analysis of published papers, with recommendations for future work. *Int J Osteoarcheol*. 2008;18(6):600-613.
- Richards MB, Sykes BC, Hedges REM. Authenticating DNA extracted from ancient skeletal remains. *J Archaeol Sci*. 1995;22(2):291-299.
- Scholz M, Pusch CM. An efficient isolation method for high-quality DNA from ancient bones. *Trends Genet*. 1997;13(6):249.
- Pusch CM, Bachmann L. Spiking of contemporary human template DNA with ancient DNA extracts induces mutations under PCR and generates non-authentic mitochondrial sequences. *Mol Biol Evol*. 2004;21(5):957-964.
- Pusch CM, Bachmann L, Broghammer M, Scholz M. Internal Alu-polymerase chain reaction: a sensitive contamination monitoring protocol for DNA extracted from prehistoric animal bones. *Anal Biochem*. 2000;284(2):408-411.
- Pyeritz RE, McKusick VA. The Marfan syndrome: diagnosis and management. *N Engl J Med*. 1979;300(14):772-777.
- De Paeppe A, Devereux RB, Dietz HC, Hennekam RC, Peyeritz RE. Revised diagnostic criteria for the Marfan syndrome. *Am J Med Genet*. 1996;62(4):417-426.
- Wilner HI, Finby N. Skeletal manifestations in the Marfan syndrome. *JAMA*. 1964;187:490-495.
- Carter H, Mace AC. *The Tomb of Tut-Ankh-amun*. Vol 2. London, England: Cassell & Co; 1927.
- Harrison RG, Abdallah AB. The remains of Tutankhamun. *Antiquity*. 1972;46:8-14.
- Harris JE, Wente EF. *An X-Ray Atlas of the Royal Mummies*. Chicago, IL: University of Chicago Press; 1980.
- Hawass Z, Shafik M, Rühli F, et al. Computed tomographic evaluation of pharaoh Tutankhamun, ca. 1300 BC. *Ann Serv Antiq Egypte*. 2009;81:159-174.
- Germer R. *Die Heilpflanzen der Ägypter*. Zürich, Switzerland: Artemis & Winkler; 2002.
- Westendorf W. *Erwachen der Heilkunst: die Medizin im alten Ägypten*. Zürich, Switzerland: Artemis Verlag AG; 1992.
- Cunha CB, Cunha BA. Brief history of the clinical diagnosis of malaria: from Hippocrates to Osler. *J Vector Borne Dis*. 2008;45(3):194-199.
- Sallares R, Bouwman A, Anderung C. The spread of malaria to southern Europe in antiquity: new approaches to old problems. *Med Hist*. 2004;48(3):311-328.
- Cheng Q, Cloonan N, Fischer K, et al. Stevor and rif are *Plasmodium falciparum* multicopy gene families which potentially encode variant antigens. *Mol Biochem Parasitol*. 1998;97(1-2):161-176.
- Kiwanuka GN. Genetic diversity in *Plasmodium falciparum* merozoite surface protein 1 and 2 coding genes and its implications in malaria epidemiology: a review of published studies from 1997-2007. *J Vector Borne Dis*. 2009;46(1):1-12.
- Mlambo G, Sullivan D, Mutambu SL, et al. Analysis of genetic polymorphism in select vaccine candidate antigens and microsatellite loci in *Plasmodium falciparum* from endemic areas at varying altitudes. *Acta Trop*. 2007;102(3):201-205.
- Harrison RG. An anatomical examination of the Pharaohic remains purported to be Akhenaten. *J Egypt Archaeol*. 1966;52:95-119.
- Harrison RG, Connolly RC, Abdalla A. Kinship of Smenkhkare and Tutankhamun demonstrated serologically. *Nature*. 1969;224(5217):325-326.
- Huppertz A, Wildung D, Kemp BJ, et al. Nondestructive insights into composition of the sculpture of Egyptian Queen Nefertiti with CT. *Radiology*. 2009;251(1):233-240.
- Freed RE, Markowitz YJ, D'Auria SH. *Pharaohs of the Sun: Akhenaten; Nefertiti; Tutankhamun*. London, UK: Thames & Hudson; 1999.
- Diethelm L, Olsson O, Strnad S, Vieten H, Zuppinger A. *Handbuch der medizinischen Radiologie V/4, Skeletterkrankungen*. Berlin, Germany: Springer; 1976.
- Reeves N. *The Complete Tutankhamun: The King, the Tomb, the Royal Treasure*. London, UK: Thames & Hudson; 1990.
- Saleh M, Sourouzi H. *Official Catalogue of the Egyptian Museum, Cairo*. Mainz, Germany: Verlag Philipp von Zabern; 1987. Carter 540, Carter 551, Catalog No. 188.
- Saleh M, Sourouzi H. *Official Catalogue of the Egyptian Museum, Cairo*. Mainz, Germany: Verlag Philipp von Zabern; 1987. Carter 108, Catalog No. 178.
- Leek F. *The Human Remains From the Tomb of Tutankhamun*. Oxford, UK: Tutankhamun Tomb Series V; 1972.
- Bogdonoff MD, Crellin JK, Good RA, et al. *The Genuine Works of Hippocrates*. Birmingham, UK: Classics of Medicine Library; 1985.
- Joy DA, Feng X, Mu J, et al. Early origin and recent expansion of *Plasmodium falciparum*. *Science*. 2003;300(5617):318-321.
- Bianucci R, Mattutino G, Lallo R, et al. Immunological evidence of *Plasmodium falciparum* infection in an Egyptian child mummy from the Early Dynastic Period. *J Arch Sci*. 2008;35(7):1880-1885.
- Sallares R, Gomzi S. Biomolecular archaeology of malaria. *Anc Biomol*. 2001;3:195-213.
- Taylor GM, Rutland P, Molleson T. A sensitive polymerase chain reaction method for the detection of *Plasmodium* species DNA in ancient human remains. *Anc Biomol*. 1997;1:193-203.
- Zink A, Haas CJ, Herberth K, Nerlich AG. PCR amplification of *Plasmodium* DNA in ancient human remains. *Anc Biomol*. 2001;3:293.
- Nerlich AG, Schraut B, Ditttrich S, Jelinek T, Zink AR. *Plasmodium falciparum* in ancient Egypt. *Emerg Infect Dis*. 2008;14(8):1317-1319.
- Ntoumi F, Ngoundou-Landji J, Lekoulou F, Luty A, Deloron P, Ringwald P. Site-based study on polymorphism of *Plasmodium falciparum* MSP-1 and MSP-2 genes in isolates from two villages in Central Africa. *Parasitologia*. 2000;42(3-4):197-203.
- Issifou S, Ndjikou S, Sanni A, Lekoulou F, Ntoumi F. No influence of the transmission season on genetic diversity and complexity of infections in *Plasmodium falciparum* isolates from Benin. *Afr J Med Med Sci*. 2001;30(suppl):17-20.
- Nunn JF. *Disease*. Cairo, Egypt: American University in Cairo Press; 2001.
- Strouhal E. *Life of the Ancient Egyptians*. Cairo, Egypt: American University in Cairo Press; 1992.
- Herodotus. *The Histories*. Waterfield R, trans. Oxford, UK: Oxford University Press; 2008:130-131.
- Hviid L. Naturally acquired immunity to *Plasmodium falciparum* malaria in Africa. *Acta Trop*. 2005;95(3):270-275.
- Diener H. *Fachlexikon ABC Arzneipflanzen und Drogen*. Frankfurt am Main, Germany: Verlag Harri Deutsch Thun; 1986.
- Germer R. *Die Pflanzenmaterialien aus dem Grab des Tutankhamun*. Hildesheim, Germany: Hildesheimer ägyptologische Beiträge; 1989.
- Germer R. *Handbuch der altägyptischen Pflanzen: Philippika, Marburger altertumskundliche Abhandlungen 21*. Wiesbaden, Germany: Harrassowitz Verlag; 2008.
- Neuwinger HD. *African Traditional Medicine: a Dictionary of Plant Use and Applications*. Stuttgart, Germany: Medpharm Scientific; 2000.
- Ghazanfar SA. *Handbook of Arabian Medicinal Plants*. Boca Raton, FL: CRC Press; 1994.